

## **How to use Stem Cells Obtained from Peripheral Blood in Dermatology and Ophthalmology**

Marco Poletti, DVM; Carlotta Gabbiani, DVM; Jan Spaas, DVM; Graziella Zohar, DVM; Valentina Martini, BS, PhD; and Alessandra Gambacurta, BS, PhD.

Authors' address: località Pizzo Volpino snc, Sutri 01015 Viterbo, Italy; Dept. of Experimental Medicine and Sciences, Faculty of Medicine and Surgery, University of Roma "Tor Vergata";  
e-mail: [marcopoletti@libero.it](mailto:marcopoletti@libero.it)

### **Abstract**

We present how to use Peripheral Blood Stem Cells (PBSCs), obtained with a new method, in the therapy of spontaneous eye and skin diseases by local and systemic application; no side effects were observed after 6 years from the first administration in horses that were treated with this therapy. For the first time a regenerative therapy uses stem cells that, as shown by cytofluorimetric analysis, express all the typical markers characterizing pluripotent stem cells.

### **Introduction**

Regenerative therapies begin to be more widely used in veterinary medicine; several scientific studies were developed in tendons and ligaments injuries using bone marrow Mesenchymal Stem Cells (MSCs)<sup>1-5</sup> or adipose tissue derived stem cells (ADSCs)<sup>6-7</sup>. Our previous studies focused on the use of stem cells obtained from peripheral blood in orthopedic diseases<sup>8</sup>. Now we want to propose an innovative subject for the veterinary medicine. Although several reports discuss the use of stem cells in human oculistic<sup>9-16</sup> and dermatologic<sup>17-18</sup> diseases, this technique has not been previously tested in veterinary medicine. Furthermore results obtained in these fields highlight macroscopically more than others the therapeutic qualities of these stem cells. The stem cells used in veterinary medicine, from bone marrow or even from adipose tissue, are not typified. This has prevented, so far, the production of a homogenous and quantifiable cell population, and therefore the development of specific therapeutic protocols. The PBSCs used in this work express all the typical markers characterizing pluripotent stem cells, as shown by cytofluorimetric analysis<sup>19</sup>. Isolation of pluripotent PBSCs from equine blood provides a non-invasive source of stem cells with potentially superior cellular characteristic to other equine stem cells with regard to immune tolerance, proliferative potential and differentiation potency<sup>20</sup>. While the local administration of stem cells or progenitor cells (cells with the capacity to differentiate into a specific type of cell and that can only divide a limited number of times) is a well established technique, the intravenous (IV) inoculation represents an innovative method. Several scientific works reported on the IV

administration of mesenchymal stem cells in animal models<sup>21-24</sup> and humans<sup>25</sup> for the treatment of cardiovascular and neurologic diseases. In addition, blood stem cells obtained with the apheresis technique are commonly in use, associated with chemotherapy, for the treatment of some kinds of human leukaemia. Recently it was demonstrated that the experimental IV injection of progenitor cells obtained from adipose tissue in people with Multiple Sclerosis has given encouraging results<sup>26</sup>. Our protocol of obtaining and using stem cells has several innovative characteristics compared to the past proposals in regenerative medicine:

- 1- An easy way to get biological material, a blood sample of about 5 ml
- 2- short processing time to have cells, about 72 hours
- 3- obtaining of a typified and quantified cell population
- 4- chance to administrate in a systemic way that

Before proving in vitro the ability of PBSCs to get to the ill areas with cell migration essay, we saw the effects, in vivo, of these cells in systemic diseases after IV administration.

Sometimes in this work we refer to other interesting clinic cases treated by us with this technique, that correlate to the pathologies we are expounding. We show the beneficial effects of these cells over a long time and the lack of side effects. In six years we made more than 10.000 inoculations, the 80% in horses, and the 20% in dogs<sup>27</sup> and recently in some cats.

### **Material and methods:**

In this paper we use stem cells directly obtained from mammal's peripheral blood cells (Patent Thankstem S.r.l.<sup>a</sup>).

The phenotypic analyses on sorted stem cells by FACS Aria II identify at least three subpopulations:

- A typical hematopoietic stem cell population, positive for CD90, CD117 and CD34
- A "mesenchymal stem cell like" population, showing CD105, CD50 expression
- A "pluripotent-like stem cells" population, expressing the intracellular transcription factors Sox2, Oct3/4 and Nanog. These factors have been shown to be strongly involved in the maintenance of the undifferentiated state of pluripotent cells.

### Local and Intravenous therapy:

The local inoculations are made in the 3 wounds and in 1 "non –neoplastic exuberant granulation" from 1 to 4 times using 26 gauge needles, in the very extensive wounds, above all along the edges, in exuberant granulation tissue in the whole mass. In the corneal ulcers PBSCs drops were instilled in the eyes 3 or more times a day for 10 days, until the cells are in the stable state. Normally we associate both the local administration and the jugular IV, instead this one can be practised leaving aside the local use of the cells. Only in some cases the PBSCs are inoculated straight into the pathologic district's vein. In the two cases reported to demonstrate that there were no side effects in

the long time, PBSCs were inoculated IV, intra-joint and intra-ligament. The therapeutic protocol is affected by a lot of variables: number of cells used, cellular percentage between different types, local and/or systemic administration, number of therapeutic cycles and time between one cycle and another. We select the protocol on the ground of the pathology and the individual characteristics. We are working on this therapy in order to obtain a protocol that we will be able to make public soon.

### Cases treated

#### DERMATOLOGY

The treatment with PBSCs was used in 4 dermatological cases, 3 severe wounds resistant to the classical therapies and 1 case of serious granulation tissue.

Case 1: mare 11 year old, clostridiosis after trauma on the cranial surface of metatarsal bone; 2 surgeries with removal of extensor tendon. Despite the daily various local and systemic treatments, in 1 year the wound didn't recover and sometimes the bone reappeared through the necrotic tissue; this animal should have been put down. PBSCs were used with local and intravenous administration every 25 days for 4 times. The horse recovered in about 100 days with the chance to become a broodmare (Fig.1).

Case 2: 16 yr gelding horse jumper, wound in the medio cranial surface of hock not healed in 1 year. 1 local and IV administration with total recovery in 40 days with no relapses.

Case 3: 26 year gelding horse jumper at rest, deep wound with exposition of the bone on the medial surface of the tibia. The resolution was hard because of the dimension, the exposition of the bone, the age of the horse and his general body conditions. 21 days after the trauma was inoculated locally and IV with PBSCs, again after 50 days. He had been resting for about 8 years, at the age of 27 year he started again to carry out a light show jumping activity (Fig. 2).

Case 4: 26 year gelding horse jumper at rest, non - neoplastic exuberant granulation after surgery with the tendency to growth and ulceration on the palmar surface of metatarsal bone. At the first examination the horse had been in treatment for 30 days with gentamicin and penicillin and appeared to be very stressed. Therefore the owner did not want his horse to undergo further surgery so PBSCs were administrated locally and IV. After 10 days the nodular proliferative lesion was 1-2 cm bigger, but more homogeneous, he had another IV administration. 10 days later the mass had decreased and was more organized and we did another IV and local administration. 60 days after we did the last injection IV and with local perfusion in the digital artery<sup>28</sup>. After 15 days the horse was completely recovered (Fig. 3). The horse stopped having antibiotics during our treatment and his general body condition improved enormously. During the whole time the horse was treated also with salicylic acid and oil containing neem oil, hypericum perforatum and olive oil<sup>b</sup>, but these remedies alone never solved a exuberant granulation of this dimension (as previously

reported these kind of pathology are at the moment incurable with traditional medical therapies).

## OPHTHALMOLOGY

Case 5: 12 year gelding horse jumper, hornet sting on the cornea. 15 days treatment with antibiotics and anti-inflammatory with no improvements. One administration of PBSCs IV and by local instillation. We saw the resolution in 100 days.

Case 6: 20 yr gelding, with superficial non-healing ulcer<sup>29-30</sup> (indolent-like corneal ulcers) treated for 6 months with different broad spectrum antibiotics and anti-inflammatory drugs. Debride carried out twice with no improvement. One administration of PBSCs IV and with local instillation. The recovery was gradual and definitive in 100 days. It's evident (Fig. 4) the better body condition of the horse that, in the meantime had not changed his ménage and didn't receive any other support therapies.

Case 7: 2 year stallion, retinal detachment. After some days of miosis and total bilateral blindness was made a diagnosis of bilateral retinal detachment (incomplete in the right eye, almost complete in the left eye) (Fig.5). The possible causes were considerate: infective, congenital, metabolic, toxic, immune-mediated and idiopathic. With 40 days of systemic steroid and broad spectrum antibiotics therapy the symptomatology wasn't change. Therefore the opinion of more than one eye specialist was that the horse couldn't recover the sight anymore. 50 days after the first eyes examination were administrated PBSCs IV. 135 days after the horse started to adjust the pupil, so the optic nerve worked again. 165 days after the horse began to see. 6 months from the administration the horse was able to see, therefore he could jump free some cross-poles. Indeed the ultrasound evaluation of the eyes revealed no much improvements in the right eye, but in the left one, where the opening situation was mainly compromised, displayed a nearly complete "restitutio ad integrum" (Fig.6).

### Cases to prove no side effects in 6 years administrations

The 2 cases reported to prove the no onset of any side effects received PBSCs IV, and sometimes locally, 3-4 times a year for 4 and 6 years. We deduce the good state of health from the clinic evaluation and the excellent results obtained in sport events.

Case 8: 21 years gelding jumping pony; when he was 16 he had post colic laminitis continued chronically for 1 year (Fig. 7). Then he started the therapy with PBSCs IV 3-4 times a year. Now he is 21 and goes on with jumping events let win and enjoy many children (Fig.8).

Case 9: 15 years mare horse jumping. When she was 7 she had a degenerative arthritis in the fetlock and a chronic injury of the lateral branch of the suspensory ligament in the left forelimb. After 2 years of conservative treatments the fetlock joint didn't respond anymore to the cortisone infiltration and the suspensory ligament seriously relapsed. The mare was breed and she had PBSCs IV, in the fetlock joint and in the suspensory ligament's injury before coupling. During the pregnancy and the lactation she received PBSCs IV for 4 times. The foal was born healthy and

strong. After foal weaning we administrated again PBSCs IV, in the fetlock joint and in the suspensory ligament. 3 months after she started to training. Now she is 15 and she performed her first show jumping Grand Prix with good results. The foal now is 4 years old, he has good results in show jumping in Belgium and he is a very promising stallion.

## Results

Table 1 summarizes the results from the 4 dermatological cases; table 2 summarizes the results from 3 ophthalmological cases.

**Table 1. Characteristics of 4 Dermatological Equine Cases Treated with PBSCs**

Signalment	Affected region	Before surgery	Diagnosis	Size	Treatment	Outcome
11 yr mare horse jumping	Cranial surface of metatarsal bone	twice	Wound therapy resistant	16x18cm	4 administrations intravenous & local every 25 days	Broodmare
16 yr gelding horse jumping	Medio Cranial surface of hock	no	Wound therapy resistant	7x3 cm	1 administration intravenous and local	Show jumping
26-yr gelding horse jumping at rest	Medial surface of tibia	no	Deep wound with exposition of the bone	12x8 cm	2 local administration+3 intravenous	Return to little show jumping
26-yr gelding horse jumping	Palmar surface of metatarsal bone	1 time	No neoplastic exuberant granulation	13x7 cm	2 local adm.+4 intravenous+1 local perfusion	At rest

**Table 2. Characteristics of 3 Ophthalmological Equine Cases Treated with PBSCs**

Signalment	Affected region	Diagnosis	Treatment	Outcome
12 yr gelding jumping horse	Cornea	Hornet sting	1 PBSCs IV & local instillation	Show jumping
20 yr gelding	Cornea	Superficial non healing cornea ulcer	1 PBSCs IV & local instillation	Return to activity
2 yr stallion jumping horse	Retina & optic nerve	Retinal detachment	1 PBSCs IV	In activity

The 3 complicated wounds, unsolvable with classical treatment, were solved from 40 to 120 days. The no neoplastic exuberant granulation solved in 120 days. This recovery proves also that the hyperproliferation is not a side effect of the PBSCs administration.

The corneal ulcers, with no response to the classical treatment, recovered in about 100 days.

The complete retinal detachment in the left eye healed of the 100%.

## Conclusions

This technique, revolutionary for medicine, helped us to approach easily and with no side effects pathologies considered up today incurable or unlikely solved. The great therapeutic support noticed with the only IV injection will quickly open the way to the application in human medicine. Actually the administration of these cells is considered like an auto transfusion. The procedure is licensed and is not put on sale in veterinary field to avoid application mistakes that would compromise the imminent employment in human medicine. The experimentation carried out in these 6 years wanders from the traditional one because it's not standardized on laboratory animals with caused diseases, but founded on animals more similar to the human and with spontaneous diseases. It was a good choice because it respected our ethical values and allowed us to obtain results more innovative than the others on stem cells research.

## References and Footnotes

1. Herthel DJ. Enhanced suspensory ligament healing in 100 horses by stem cells and other bone marrow components. *Proceedings American Association of equine Practitioners* 2001;47: 319-321.
2. Fortier LA, Nixon AJ, Williams J, et al. Isolation and chondrocytic differentiation of equine bone marrow-derived mesenchymal stem cells. *Am J Vet Res* 1998;59:1182-1187.
3. Smith RK, Korda M, Blunn GW, et al. Isolation and implantation of autologous equine mesenchymal stem cells from bone marrow into the superficial digital flexor tendon as a potential novel treatment. *Equine Vet J* 2003; 35, 1: 99-102.
4. Richardson LE, Dudhia J, Clegg et al. Stem cells in veterinary medicine-attempts at regenerating equine tendon after injury. *Trends in Biotechnology* 2007; 25:409-416.
5. Pacini S, Spinabella S, Trombi L, et al. Suspension of bone marrow-derived undifferentiated mesenchymal stromal cells for repair of superficial digital flexor tendon in race horses. *Tissue engineering* 2007; 12:2949-2955.
6. Suresh N SD De, Thambyah A, et al. Cell-based therapy in the repair of osteochondral defects: a novel use for adipose tissue. *Tissue Engineering* 2003;9: 4.
7. de Mattos Carvalho A, Alves ALG, Golim MA, et al. Isolation and immunophenotypic characterization of mesenchymal stem cells derived from equine species adipose tissue. *Veterinary Immunology and Immunopathology*, 2009;132:303-306.
8. Poletini M, Zohar G, Gabbiani C, et al. Application of stem cells obtained from peripheral blood in therapy of tendons, ligaments and skin's injuries, in *Proceedings*. 16<sup>th</sup> Annual Meeting of the Italian Association of Equine Practitioners (SIVE) 2010;321-322.
9. Johnson TV, Bull ND, Martin KR. Transplantation prospects for the inner retina. *Eye* 2008;1-5.
10. Limb GA, Daniels JT, Cambrey AD, et al. Current prospects for adult stem cell-based therapies in ocular repair and regeneration. *Current Eye Research* 2006; 31: 391-390.
11. Levin LA, Ritch R, Richards JE, et al. Stem cell therapy for ocular disorders. *Archives of Ophthalmology* 2004;122: 621-627.

12. Limb GA, Daniels JT. Ocular regeneration by stem cells: present status and future prospects. *British Medical Bulletin* 2008; 85: 47-61.
13. Singhal, Shweta, Bhatia, et al. Partial restoration of retinal ganglion cell (RGC) function by transplantation of neurons derived from human Müller stem cells into RGC depleted rat retina, in *Proceedings. 7<sup>th</sup> Annual Meeting of International Society for Stem Cells Research* 2009,19.
14. Xu, Guo-Tong<sup>1</sup>, Guan, et al. Transplantation rMSCS as barrier maintain and support the degeneration retina, in function by transplantation of neurons derived from human Müller stem cells into RGC depleted rat retina, in *Proceedings. 7<sup>th</sup> Annual Meeting of International Society for Stem Cells Research* 2009,19-20.
15. Maclaren RE, Pearson RA. Stem cell therapy and the retina. *Eye* 2007;21:1352-9.
16. Canola K, Angénieux B, Tekaya M, et al. Retinal stem cells transplanted into models of late stages of retinitis pigmentosa preferentially adopt a glial or a retinal ganglion cell fate. *Invest Ophthalmol Vis Sci* 2007;48:446-54.
17. Alonso L, Fuchs E. First experience in the use of bone marrow mesenchymal stem cells for the treatment of a patient with deep skin burns, in *Proceedings. Proceedings of the National Academy of Sciences* 2003;100:11830-35.
18. Bianco P, Gehron Robey P. Stem cells in tissue engineering. *Nature* 2001;414:118-121.
19. Martini V, Rotta G, Sinibaldi Salimei P, et al. Expansion and purification of peripheral blood stem cells: phenotypic characterization, in *Proceedings. 16<sup>th</sup> Annual Meeting of the Italian Association of Equine Practitioners (SIVE)* 2010;301-302.
20. Koerner J, Dobrila N, Romero JD, et al. Equine Peripheral Blood-Derived Progenitors in Comparison to Bone Marrow-Derived Mesenchymal Stem Cells. *Stem Cells* 2006; 24, 6: 1613-1619.
21. Sharma, Sushil, Brennema, et al. Bone marrow derived mononuclear cells enhance recovery in a murine model of acute ischemic stroke, in *Proceedings. 7<sup>th</sup> Annual Meeting of International Society for Stem Cells Research* 2009;30-31.
22. Blatt A, Cotter G, Leitman M, Krakover R, et al. Intracoronary administration of autologous bone marrow mononuclear cells after induction of short ischemia is safe and may improve hibernation and ischemia in patients with ischemic cardiomyopathy. *American Heart Journal* 2005; 150:986-992.
23. Mendez-Otero R, Santos AV, Giraldo-Guimarães A. Bone marrow mononuclear cells induce functional recovery and decrease neurodegeneration after cortical ischemia in rats, in *Proceedings. 7<sup>th</sup> Annual Meeting of International Society for Stem Cells Research* 2009;10.
24. Bacigaluppi M, Pluchino S, Peruzzotti Jametti L, et al. Delayed post-ischemic neuroprotection following systemic mouse adult neural stem cell transplantation involves multiple mechanisms, in *Proceedings. 7<sup>th</sup> Annual Meeting of International Society for Stem Cells Research* 2009;14.
25. Aghdami N, Nikeghbalian S, Pournasr B, et al. Autologous bone marrow stem cells in cirrhosis patients, in *Proceedings. 7<sup>th</sup> Annual Meeting of International Society for Stem Cells Research* 2009;23.
26. Riordan NH, Ichim TE, Lee R, et al. Review Open Access Non-expanded adipose stromal vascular fraction cell therapy for multiple sclerosis. *Journal of Translational Medicine* 2009;7:29.
27. Silveira ACC, Lima RS, Penha EM, et al. Harvest and characterization of mesenchymal canine stem cells from adipose tissue and bone marrow. *Veterinary Immunology and Immunopathology* 2009;128 (1),342-342.
28. Misra, Vivek, Kasam, et al. Intra-arterial delivery is safe in acute ischemic stroke, in *Proceedings. 7<sup>th</sup> Annual Meeting of International Society for Stem Cells Research* 2009;31.

29. Michau T M, Schwabentont B, Davidson M G, et al. Superficial, non-healing corneal ulcers in horses: 23 cases (1989-2003), *Vet Oftalmo*. 2003; 6: 291-297.
30. Cooley P L, Wyman M. Indolent-like corneal ulcers in 3 horses. *J Am Vet Med Assoc* 1986; 188: 295-297.
- T. M. Michau\*, B. Schwabenton†, M. G. Davidson
- a. Thankstem S.r.l., Via Manzini 21, 33100 Udine, Italy.
  - b. Hypermix®, R.I.MOS., Mirandola (Mo), Italy.

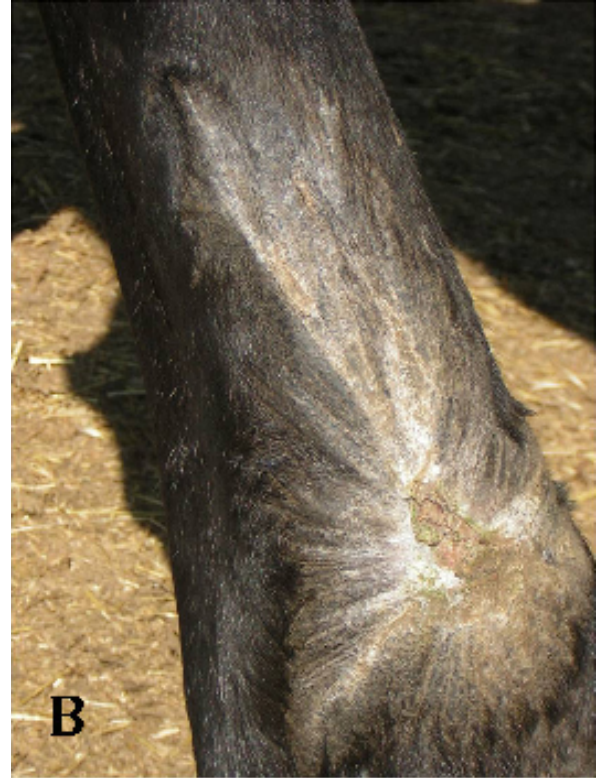
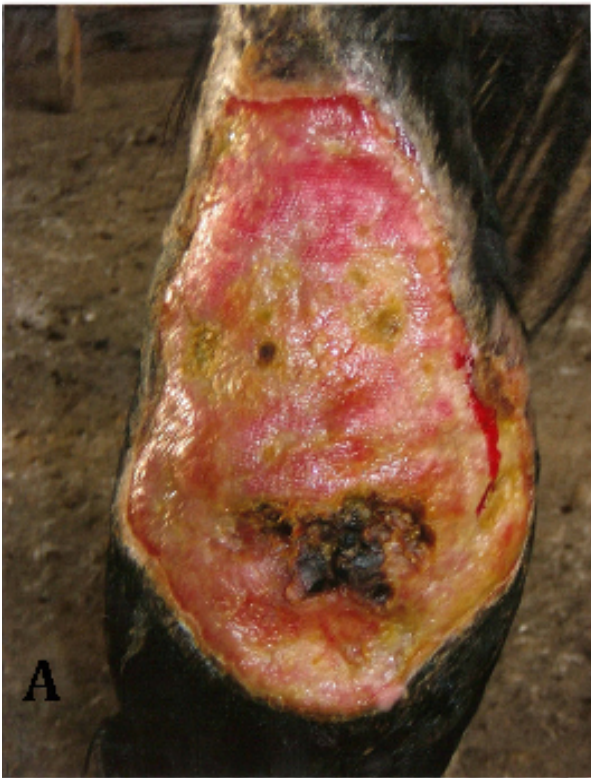

Fig. 1. Clostridiosis after trauma on the cranial surface of metatarsal bone at time 0 (A) and after 120 day (B).

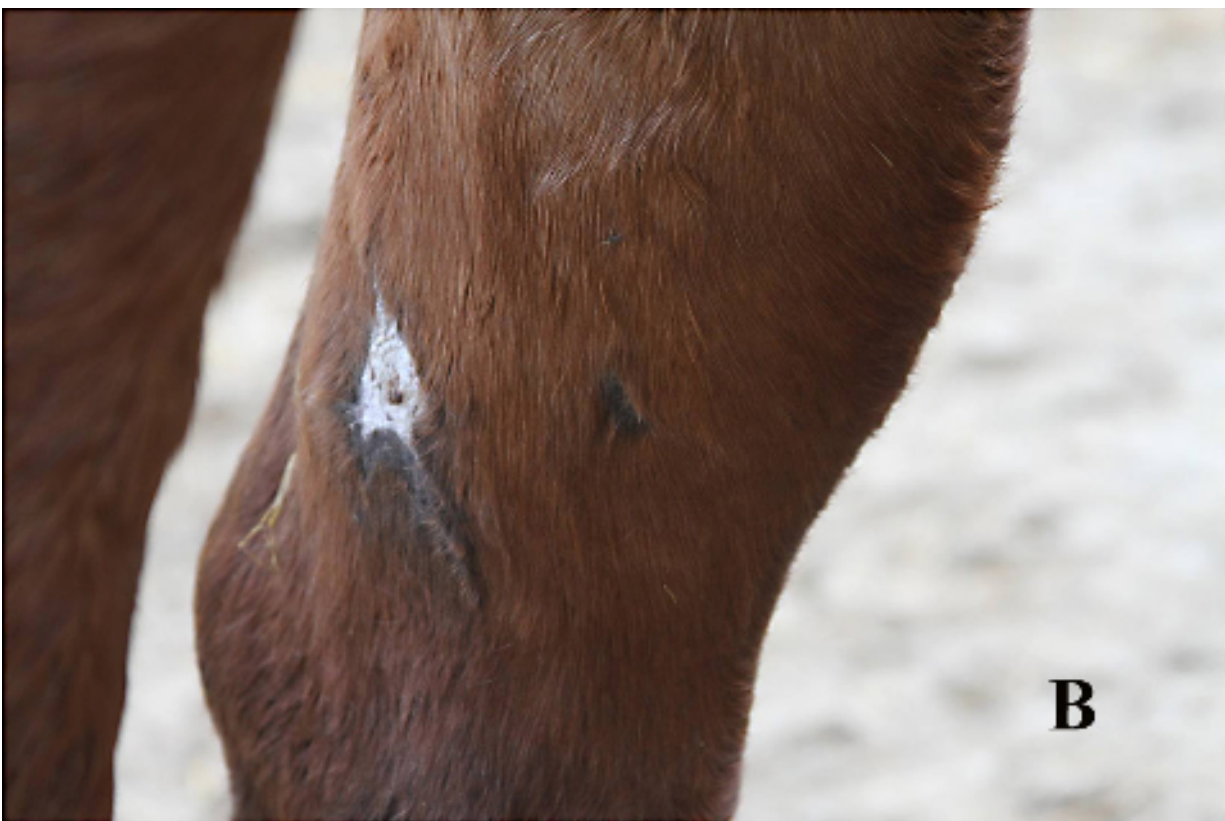
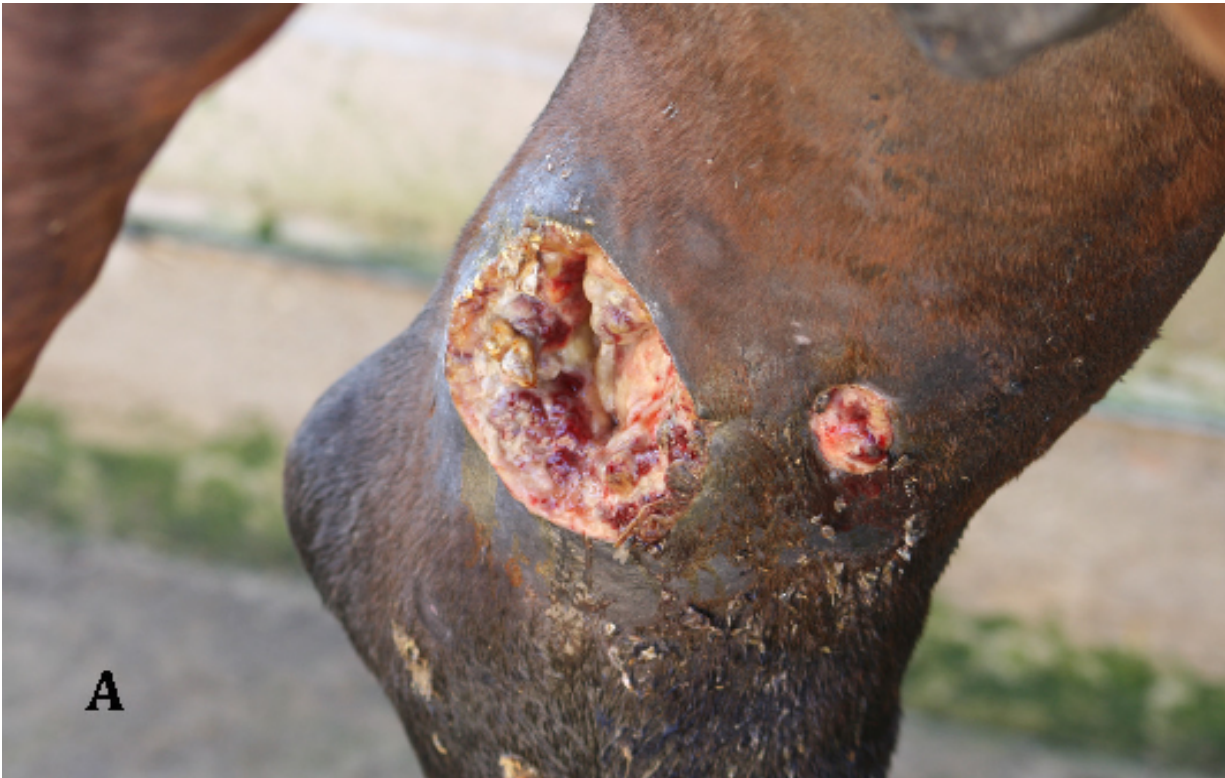
Fig. 2. Deep wound with exposition of the bone on the medial surface of the tibia at time 0 (A) and after 50 days.

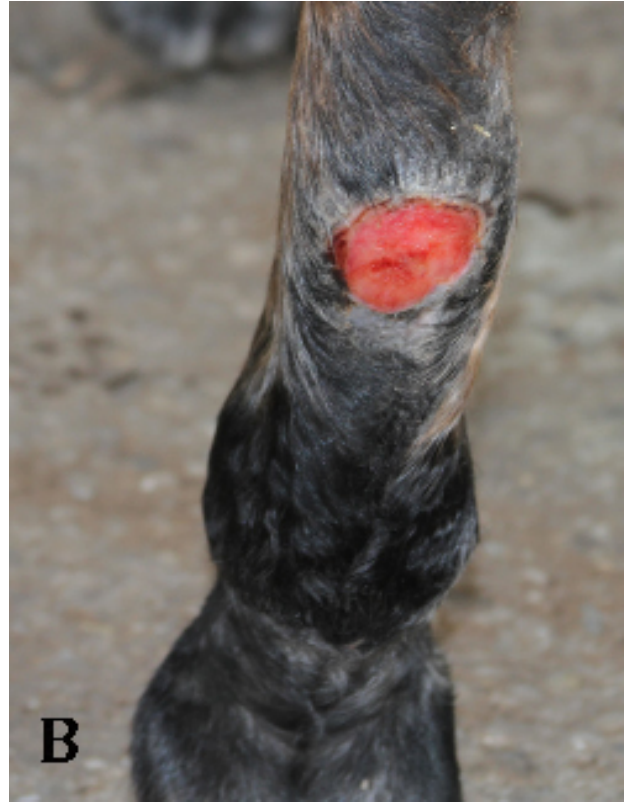
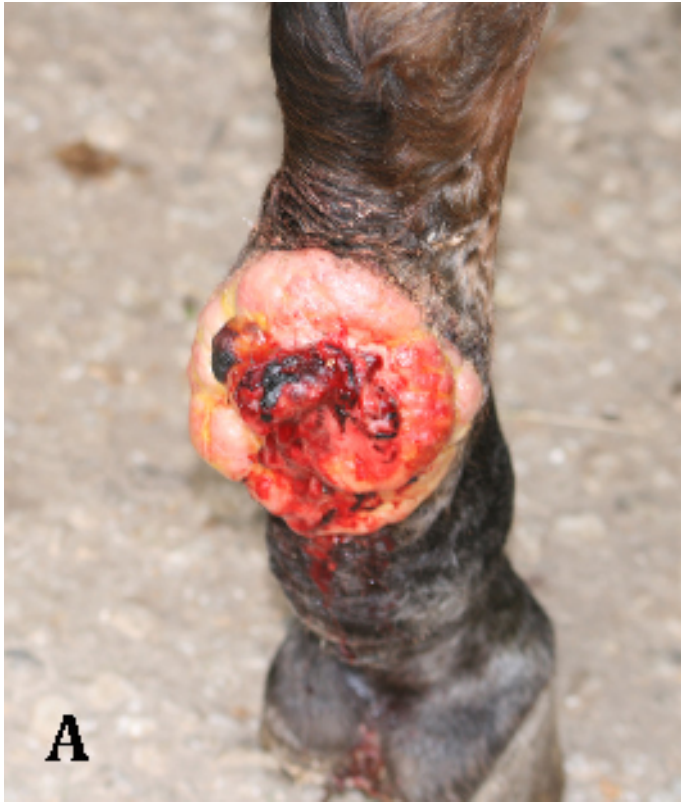
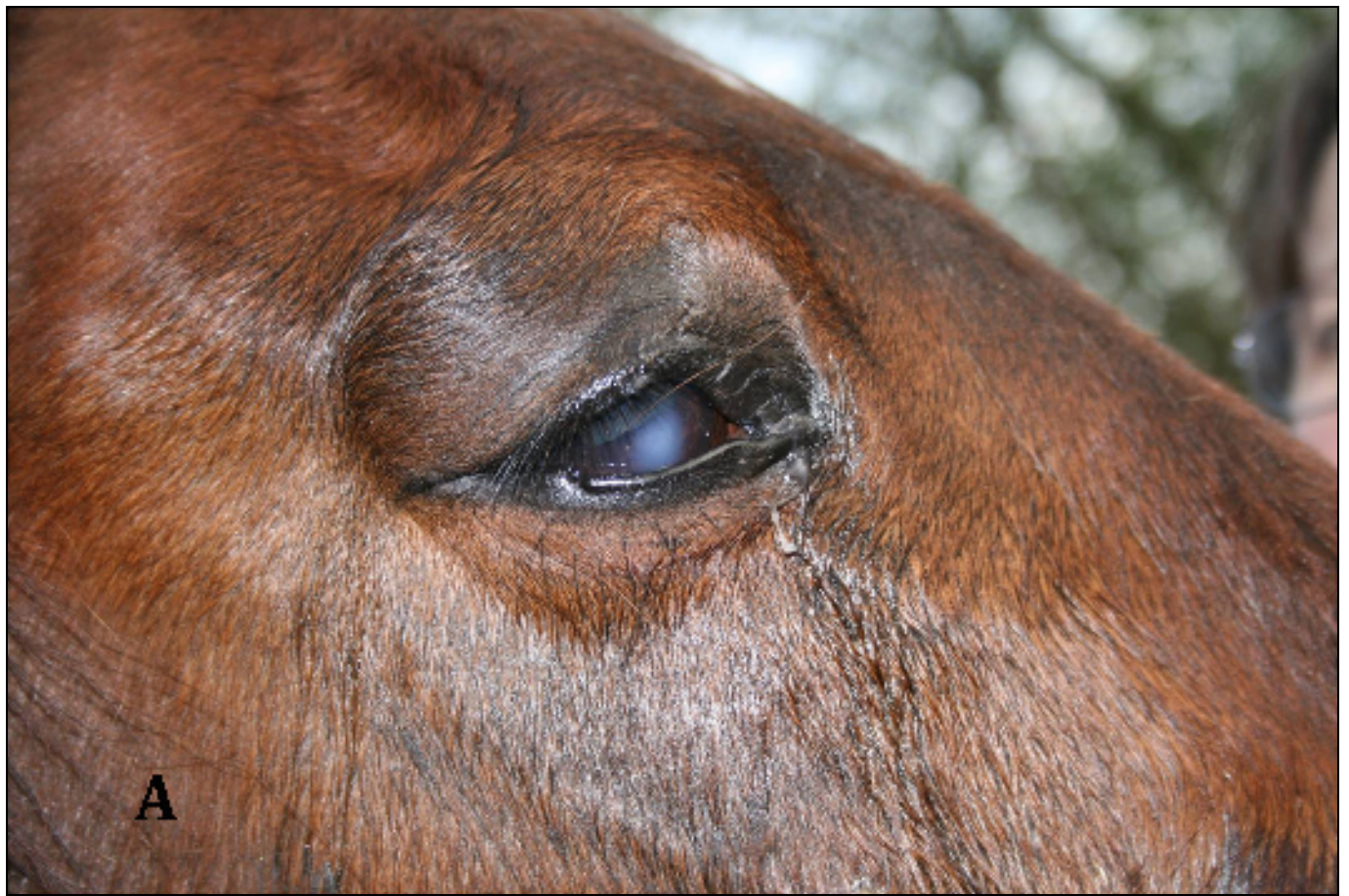Fig. 3. No neoplastic exuberant granulation after surgery with the tendency to growth and ulceration on the palmar surface of metatarsal bone at time 0 (A) and after 125 days (B).



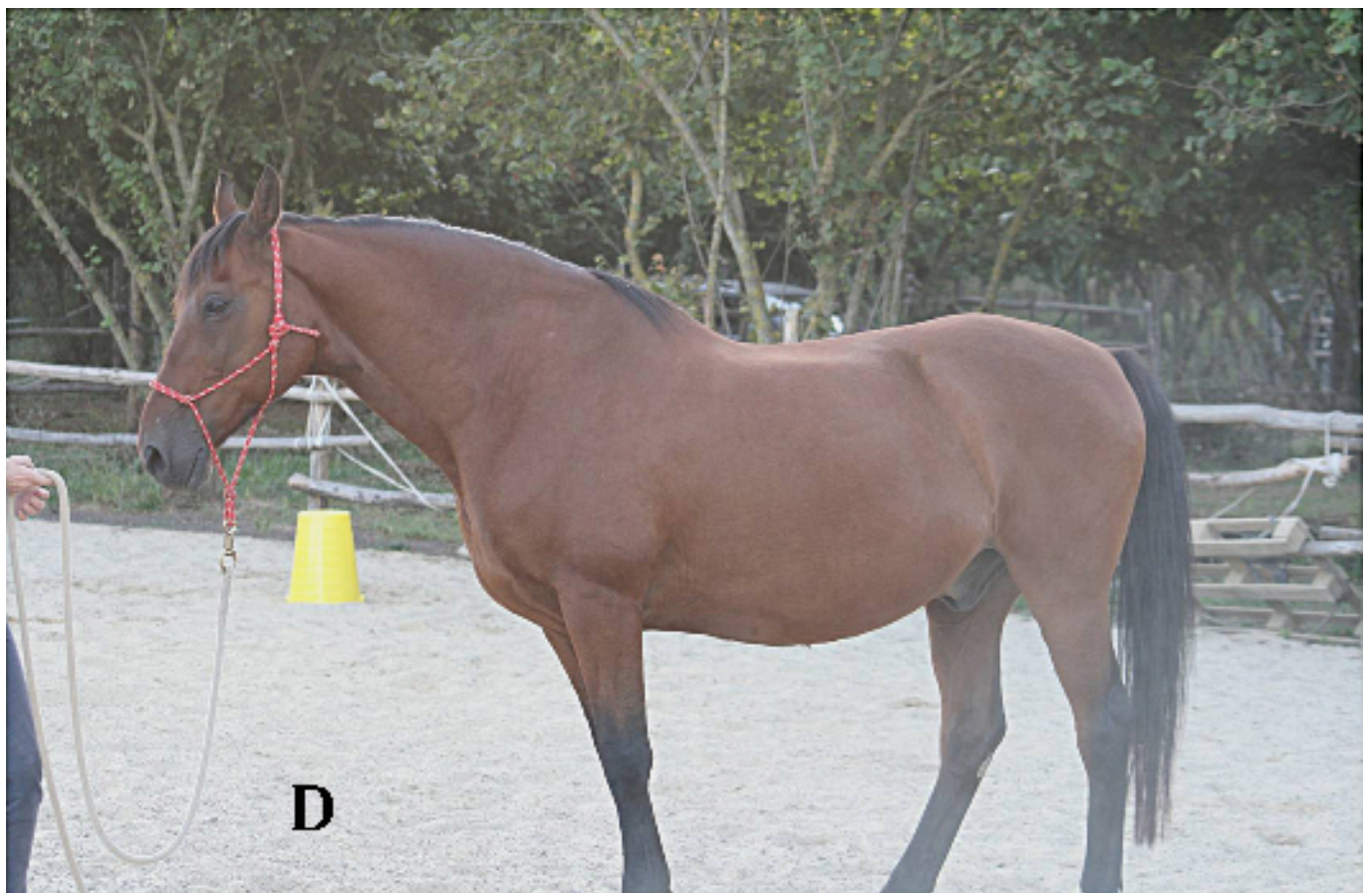
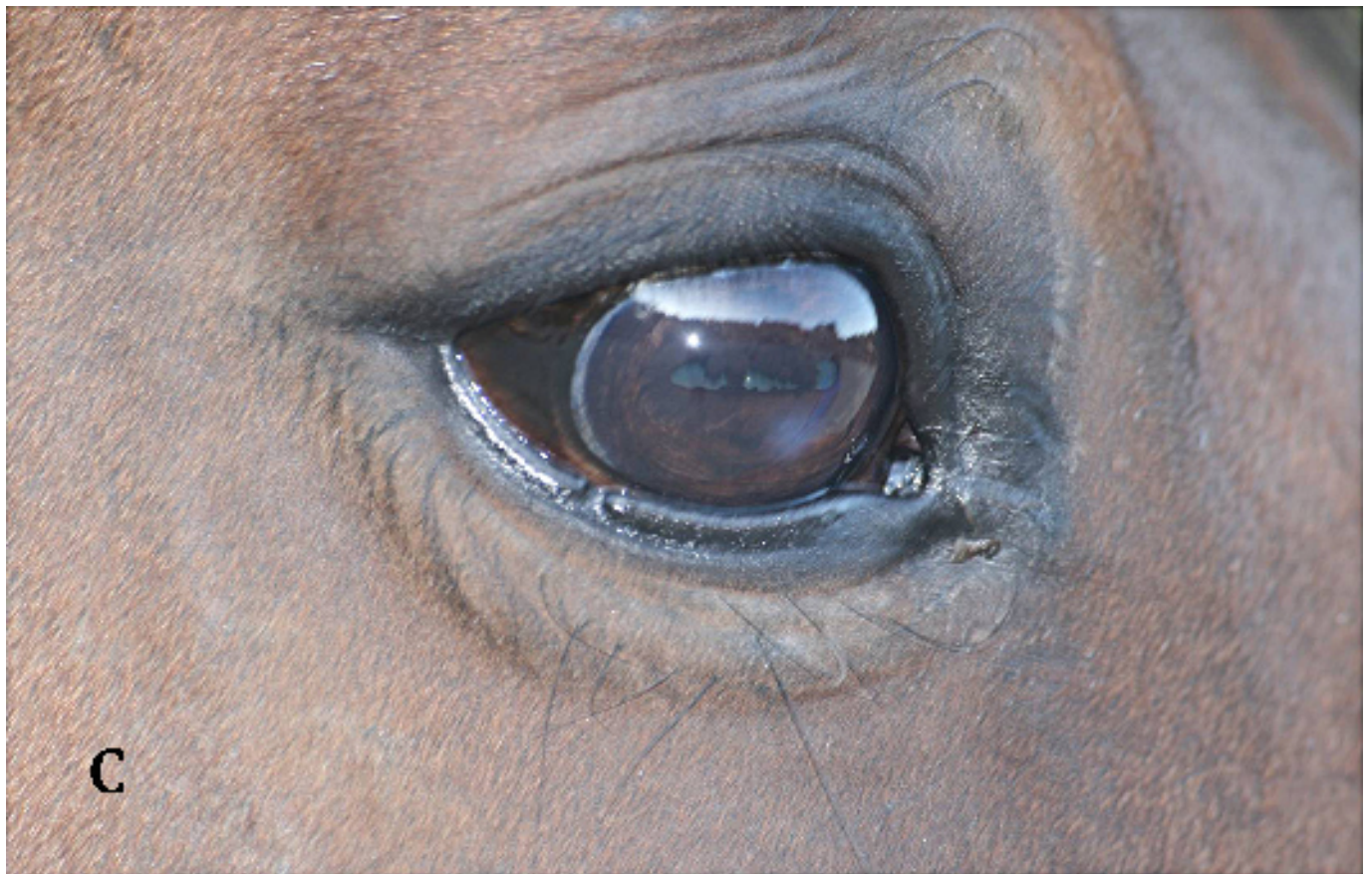
Fig. 4. Corneal Ulcer resistant to treatments in a 20 yr old horse at time 0 (A and B) and after 100 days (C and D).

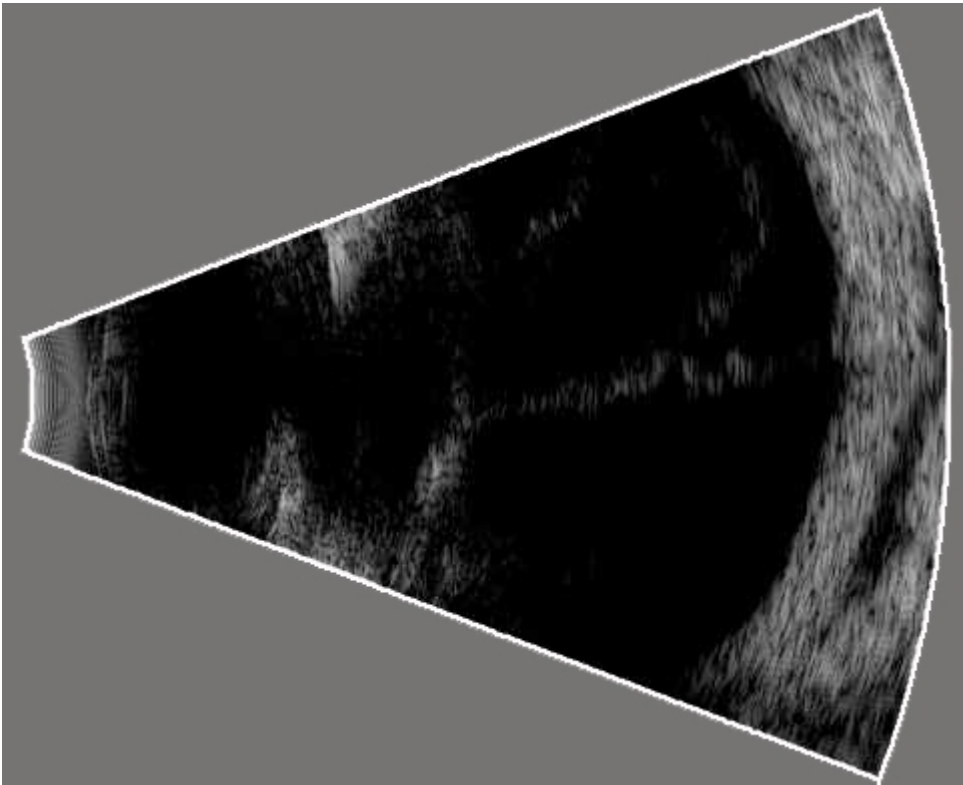


Fig. 5. Ultrasound examination shows a retinal detachment at time 0.

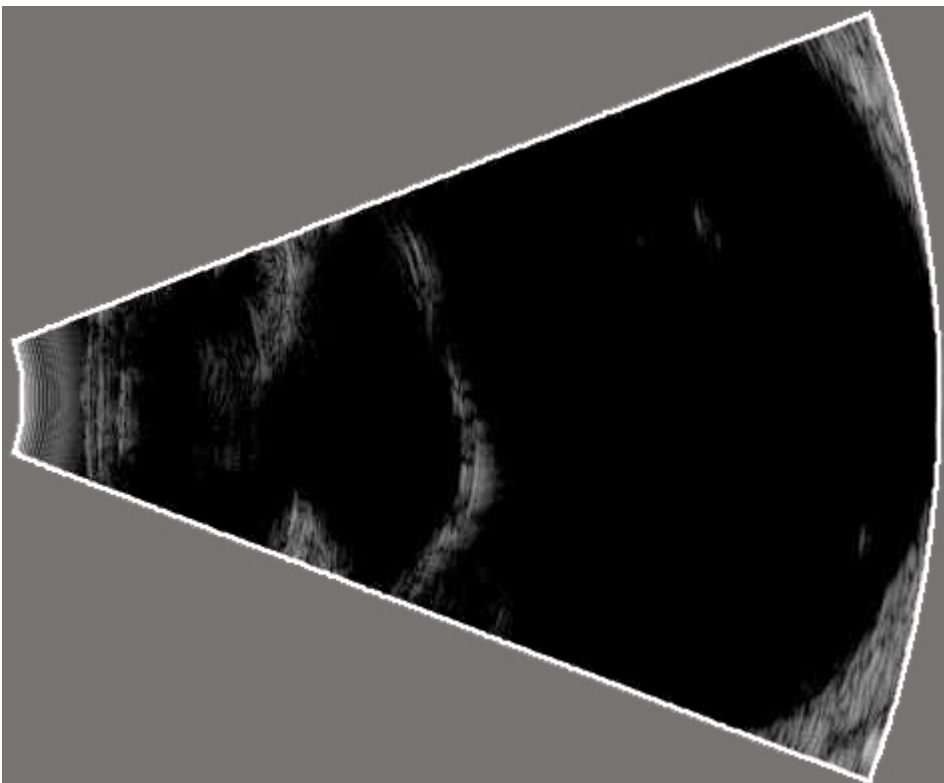


Fig. 6. Ultrasound examination shows the retina reattached after 180 days.



Fig. 7. Pony when he was 16 with post colic laminitis.



Fig. 8. The same pony 21 years old after regular administration of PBSCs for a period of 4 years.